

**CALODIUM HEPATICUM IN WHITE-TAILED JACKRABBITS IN SOUTH DAKOTA**

—White-tailed jackrabbits (*Lepus townsendii*) are common on the prairie, and an important species in prairie food webs (Lim 1987). Although it has been suggested that jackrabbits have cyclic populations (Donoho 1972, Gross et al. 1974, Anderson and Shumar 1986), there is concern that a general downward trend exists in populations in the Northern Great Plains (Feldhamer et al. 2003). Disease incidence in white-tailed jackrabbits is poorly known (Feldhamer et al. 2003), but may be an important factor in population changes. Tularemia, a disease caused by bacteria (*Francisella tularensis*), occurs throughout the Northern Hemisphere and can affect many mammals including hares, rabbits and rodents (Feldhamer et al. 2003). As part of a larger study, our objective was to determine the incidence of tularemia in white-tailed jackrabbits in South Dakota. We collected livers from 314 white-tailed jackrabbits throughout 44 counties in South Dakota from June 2004 to August 2005. We examined all livers for any lesions and evidence of infection, and only 16 abnormal livers were found. We submitted these livers to the Animal Disease Research and Diagnostic Laboratory at South Dakota State University for microscopic and bacterial examinations.

We detected no evidence of bacterial infection (including *F. tularensis*) in 298 examined livers or 16 abnormal livers. However, 4 of the livers were infected with *Calodium hepaticum*, a nematode parasite primarily detected in rodents and in some lagomorphs (Anderson 2000). The

remaining livers had lesions characterized by hemorrhage, inflammation, or necrosis with undetermined causes.

Livers infected with *C. hepaticum* were characterized by multifocal, 1–5 mm pale foci throughout the liver. Microscopically, liver lesions were multifocal and ranged from small aggregates of *C. hepaticum* eggs (Fig. 1) surrounded by scant mature fibrous connective tissue to large areas of necrosis and mixed inflammation associated with *C. hepaticum* eggs and/or adults (Fig. 2). Inflammation ranged from mostly suppurative to pyogranulomatous characterized by central suppuration, surrounded by accumulations of macrophages, giant cells, and mineral.

The life cycle of *C. hepaticum* begins with the final host's ingestion of embryonated eggs, which are present in animal flesh or contaminated material. These eggs then hatch in the cecum and the first stage larva penetrates the cecal wall and migrates to liver via the portal vein in a few days. The parasite goes through 2 additional larval stages before reaching maturation in 21–28 days. Adult males (15–30 × 0.06mm) and females (100 × 0.2 mm) must be present in the liver parenchyma for productive infection. The female deposits eggs (45–60 × 30 μm and characterized by two polar plugs) in the parenchyma and the male and female die at approximately 40 and 60 days, respectively. The unembryonated eggs persist in the liver until the host is eaten or dies. Consequently, eggs embryonate and form the first stage larva, which can survive for a year. The cycle then begins again with the final host ingesting the mature egg (Anderson 2000, Mehlhorn 2001).

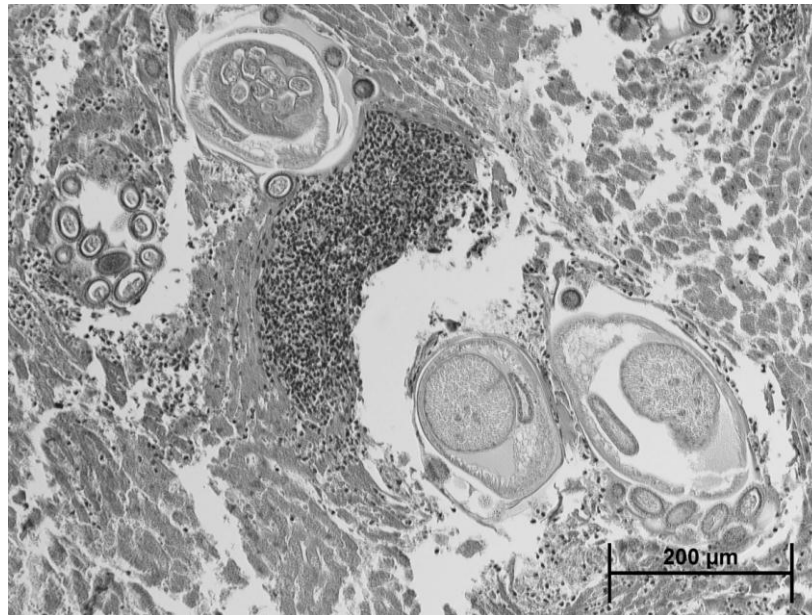


Figure 1. Section of a South Dakota white-tailed jackrabbit liver with group of bipolar operculated *Calodium hepaticum* eggs surrounded by inflammation, 2004–2005.

Previous studies documenting helminthes parasites of lagomorphs in South and North Dakota have not reported *C. hepaticum* infection in white-tailed jackrabbits (Voth and James 1965, Kletzmman and Huggins 1986). We detected *C. hepaticum* in 3 jackrabbits from Kingsbury County in eastcentral South Dakota and 1 from Perkins County in the northwest corner of the state. There was no evidence that *C. hepaticum* is having a negative effect on statewide white-tailed jackrabbit populations. However, this parasite is generally picked up by ingesting contaminated vegetations or eating rotting flesh, an unusual behavior for white-tailed jackrabbits

Funding for this research project was provided by the South Dakota Department of Game, Fish and Parks, South Dakota State University, and the Federal Aid to Wildlife

Fund (Project W-107-R, Amendment #17) administered by the South Dakota Department of Game, Fish and Parks. The South Dakota Department of Game, Fish and Parks granted a special collector's permit for this research. This study was approved as #04-A020 by the South Dakota State Institutional Animal Care and Use Committee. —Dustin J. Schaible<sup>1</sup>, Charles D. Dieter<sup>1,3</sup>, Regg D. Neiger<sup>2</sup>, and Michael B. Hildreth<sup>1</sup>. <sup>1</sup>Department of Biology and Microbiology, South Dakota State University; Brookings, South Dakota 57007, USA; <sup>2</sup>Animal Disease Research and Diagnostic Laboratory, South Dakota State University, Box 2175, North Campus Drive, Brookings, South Dakota 57007, USA. <sup>3</sup>Corresponding author email address: charles.dieter@sdstate.edu.

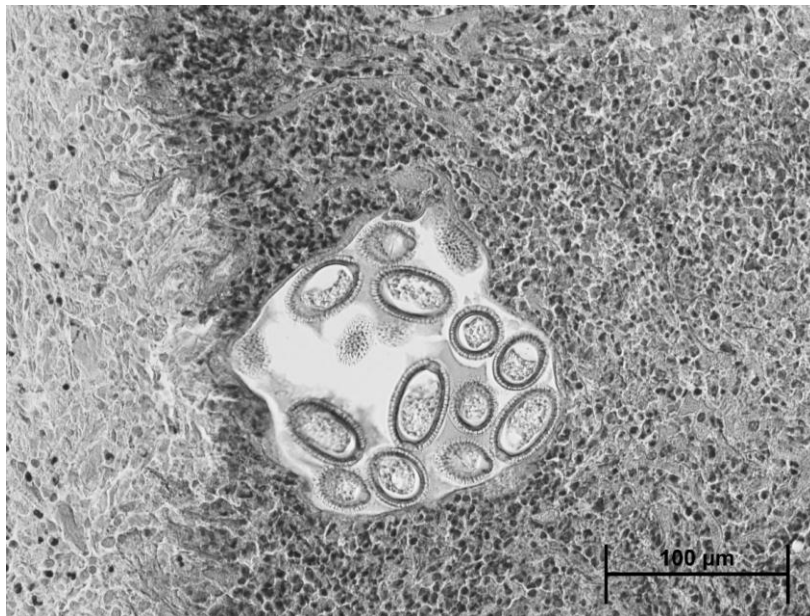


Figure 2. Section of a South Dakota white-tailed jackrabbit liver with multiple cross sections of adult *Calodium hepaticum* and several groups of eggs, 2004–2005.

#### LITERATURE CITED

- Anderson, J. E., and M. L. Shumar. 1986. Impacts of black-tailed jackrabbits at peak population densities. *Journal of Range Management* 39:152–156.
- Anderson, R. C. 2000. *Nematode parasites of vertebrates: their development and transmission*. CABI Publishing, Wallingford, United Kingdom.
- Donoho, H. S. 1972. Dispersion and dispersal of white-tailed and black-tailed jackrabbits. Pawnee National Grasslands. Thesis, Colorado State University, Fort Collins, USA.
- Feldhamer, G. A., B. C. Thompson, and J. A. Chapman. 2003. *Wild mammals of North America: biology, management, and conservation*. Johns Hopkins University Press, Baltimore, Maryland, USA.
- Gross, J. E., L. C. Stoddart, and F. H. Wagner. 1974. Demographic analysis of a northern Utah jackrabbit population. *Wildlife Monographs* 40:1–68.
- Kletzmman, G. E. and E. J. Huggins. 1986. Helminths of lagomorphs in South Dakota. *Journal of Wildlife Diseases* 22:276–278.
- Lim, B. K. 1987. *Mammalian Species, Lepus townsendii*. The American Society of Mammalogists, No. 288, Lawrence, Kansas, USA.
- Mehlhorn, H. 2001. *Encyclopedic reference of Parasitology. Capillaria Species 1:101–103*. Springer-Verlag Press, Berlin, Germany.

Voth, D. R. and T. A. James. 1965. Parasites of the white-tailed jackrabbit in southwest North Dakota. Annual Proceedings of the North Dakota Academy of Science 19:15–18.

*Submitted 29 September 2010. Accepted 20 December 2010. Associate Editor was Christopher S. DePerno.*